

MORPHOGENESIS OF THE WALL OF GLANDULAR PART OF THE STOMACH IN CHICKENS DURING POSTNATAL PERIOD OF ONTOGENESIS

N. V. DYSHLIUK,

Doctor of Veterinary Sciences, Associate Professor, Academician

V. G. Kasyanenko Department of Anatomy, Histology and Pathomorphology

<https://orcid.org/0000-0003-4753-9356>

E-mail: dushlyuk@ukr.net

National University of Life and Environmental Sciences of Ukraine,

15 Heroiv Oborony st., Kyiv 03041, Ukraine

Abstract. Knowledge about the morphological features of the structure and functions of the digestive organs provides the basis for rational and effective use of feed, prevention and treatment of gastrointestinal diseases in poultry. In this regard, the study of the morphogenesis of the digestive system in birds and the mechanisms of their regulation is of great importance.

The object of the study was the glandular part of the stomach (proventriculus) in chickens of Shaver 579 strain. The material for macro- and microscopic examinations was selected from birds at age of 1, 30, 60, 90, 120, 150, 180, 210, 240, 270, and 300 days and 1, 2, and 3 years; it was fixed in a 10% neutral formalin solution and embedded into paraffin according to conventional methods. For submicroscopic examinations, the material was selected from hens of this strain at age of 180 days. The structure of epitheliocytes in the superficial epithelium and secretory cells of the deep glands was studied in ultrathin sections. Digital indicators of research results were statistically processed by a personal computer using the Microsoft Excel program.

The glandular stomach in chickens is a direct extension of the esophagus and has the form of a thick-walled tube, the wall of which is formed by mucous, muscular, and serous membranes. The superficial epithelium of the mucosa is represented by cylindrical epithelial cells that are located within the basal membrane. They are linked to each other by different types of contacts and have a well-defined polar differentiation. The lobules of the deep glands are formed by cells with well-developed synthesizing organelles and secretory granules.

The morphogenesis of the glandular part of the stomach in chickens according to age aspect is manifested by changes in morphometric parameters of the thickness and the area of the membranes of its wall. The wall thickness increases (between the folds 4223.23 ± 189.25 and in the area of the folds $5561.32 \pm 45.01 \mu\text{m}$) unevenly in chickens up to the age of 240 days. The most developed membrane of the wall of the glandular stomach is the mucosa. Its area increases (by $82.14 \pm 0.56\%$) in chickens up to the age of 180 days, and the area of muscular and serous membranes decreases (by 15.54 ± 0.65 and $2.32 \pm 0.33\%$, respectively). In older birds, the thickness of the wall and the area of the membranes of the glandular stomach do not change significantly.

Keywords: chickens, stomach, morphometric parameters, mucosa, muscular membrane, serosa

Introduction

Poultry farming in Ukraine is the most efficient branch of animal husbandry, which provides opportunities for a short time to significantly increase the production of high-calorie dietary products – meat and eggs in order to provide the population with physiologically necessary nutrition. This is facilitated by climatic conditions and developed grain farming (Seliverstova, 2018). Knowledge of the structural and morphological features of the structure and functions of the digestive system form the basis for rational and effective use of feed, prevention and treatment of gastrointestinal diseases in poultry. In this regard, the study of the morphogenesis of the avian digestive system and the mechanisms of their regulation is of great importance.

Analysis of recent researches and publications

Birds capture with their beak and swallow unchewed feed (due to the absence of teeth), which from the esophagus enters directly into the glandular part of the stomach (Khomych et al., 2020). The latter is not clearly separated from the esophagus and differs only in thicker walls and a large number of glands that secrete digestive enzymes. The size and shape of the glandular part of the stomach depend on the amount and size of feed objects (trophic specialization) that are coming from the environment. Depending on the bird species, it can be spindle-shaped, barrel-shaped, or truncated cone-shaped (Kharchenko, 2014).

A typical feature for the mucosa in the glandular part of the avian stomach is the folding and the presence of superficial and deep glands. The superficial glands are simple tubular, located in the

lamina propria of the mucosa, and the deep glands – in the submucosa. The deep glands form lobes with a central cavity, into which numerous secretory departments open (Nasrin et al., 2012; Abumandour, 2013; Naletova, 2013). In grain-eating, herbivorous, and omnivorous birds, these glands are multilobed with a complexly branched system of ducts, and in carnivorous and insectivorous birds, they are unilobed. The deep glands produce gastric juice, under the influence of which the chemical processing of feed occurs. The optimal environment in the glandular part of the stomach is provided by hydrochloric acid, which simultaneously causes the transition of inactive pepsinogen to active pepsin. There is a species difference in proteolytic activity and acidity of the juice in birds. The gastric juice in chickens and turkeys has the greatest digestive power and acidity, and the least – geese (Naletova, 2013).

Many scientific works are devoted to the glandular part of the stomach in birds, including chickens (Ahmed et al., 2011; Dahekar et al., 2014; Demirbag et al., 2015) but some inaccuracies remain in the morphogenesis of the gastric gland wall during the postnatal period of ontogenesis.

The purpose of the study is to determine the morphological features and to establish the morphometric indicators of the growth of the glandular part of the chicken stomach in the age aspect.

Materials and methods of research

Macroscopic, microscopic, and submicroscopic methods of morphological research were used in the study. All interventions and euthanasia of birds were performed by acute exsanguination after

ether anesthesia in compliance with the requirements of the European Convention for the Protection of Vertebrate Animals Used for Experimental and Other Scientific Purposes (Strasbourg, 1986), the First National Congress on Bioethics (Kyiv, 2001), and the Law of Ukraine On Protection of Animals from Brutal Treatment (2006).

The material for macro- and microscopic examinations (glandular part of the stomach) was selected from chickens of egg-laying cross Shaver 579 at age of 1, 30, 60, 90, 120, 150, 180, 210, 240, 270, and 300 days and 1, 2 and 3 years. The birds were clinically healthy and showed no signs of disease. The research was conducted in the Scientific Laboratory of Immunomorphology of the Academician V. G. Kasyanenko Department of Anatomy, Histology and Pathomorphology, the National University of Life and Environmental Sciences of Ukraine. The selected material was labeled and fixed in a 10% aqueous solution of neutral formalin. After fixation, the material was washed in running water, dehydrated in alcohols of increasing concentration, compacted, and embedded into paraffin according to conventional methods. The paraffin-embedded material was placed on wooden blocks, and histological sections 5–10 μm thick were made by the MPS-2 sled microtome. Sections were stained with Caracci's hematoxylin and eosin, according to the Weigert and Van Gieson methods (Goralskyi et al., 2005). The area of the membranes of the glandular part of the stomach was determined by the method of "point counting" using an MBS-2 binocular microscope and a measuring grid, which is included in its kit. The wall thickness was measured using an MBI-2 microscope and an MOV-1-15x eyepiece micrometer. The results of the

studies were recorded in protocols and their figures were statistically processed using a personal computer by Microsoft Excel (Plokhinskyi, 1970; Goralskyi et al., 2005). The material for the illustrations was photographed using an Olympus microscope with a Nikon Coolpix S3100 camera.

The submicroscopic examination was performed to study the superficial epithelial cells and secretory cells of the deep glands of the glandular part of the stomach in 180-day-old chickens. The studies were performed in the Laboratory of Electron Microscopy of the Bogomolets National Medical University. The material was selected no later than 5 minutes after bird slaughter (Vlasov et al., 2011). The glandular part of the stomach was cut into pieces 1.5 mm^3 in size, fixed in 2.5% glutaraldehyde for 1 hour at a temperature of +40 $^{\circ}\text{C}$, washed with 0.1 M Na-cocadylate buffer, and fixed again in 2% osmic acid solution. Then the pieces were dehydrated in ethanol of increasing concentration and acetone and poured into an Epon-Araldite mixture according to conventional methods. The samples were placed in capsules and filled with a mixture of epoxy resins (epon and araldite), which were polymerized for 24 hours at a temperature of +37 $^{\circ}\text{C}$ and 24 hours at a temperature of +60 $^{\circ}\text{C}$. Ultrathin 50–90 nm sections were obtained on an LKB-III B ultramicrotome using disposable glass knives. Substrate films (collodion) were applied to the sections and transferred to support grids, contrasted with solutions of uranyl acetate and lead citrate, and examined under an electron transmission microscope (SELMi PEM-125K). Morphological subjects were photographed with a camera mounted in an electron microscope on black and white film and analyzed.

Results of the research and their discussion

Studies have confirmed that the glandular part of the stomach in chickens is a direct extension of the esophagus and occupies a position close to the middle sagittal plane (Langlois, 2019). It has the appearance of a thick-walled tube, which consists of the apex, the body, and the intermediate zone (isthmus), by which it is connected to the muscular part. The apex lies between the thoracic air sacs and the body lies between the lobes of the liver. The right surface of the glandular part of the stomach borders on the spleen and ileum, and the left – with the cecum. On the surface of the mucosa, the conical papillae limited by folds are visible. At their tops, the ducts of the deep glands of the stomach open.

In one-day-old chickens, the general plan of the microscopic structure of the glandular part of the stomach is the same as in adult birds. Its wall is formed by mucous, muscular, and serous membranes. The mucosa forms low longitudinal folds, which straighten when filled with feed and are represented by the epithelium, lamina propria, muscularis externa, and submucosa. The data of other researchers (Hassouna, 2001; Aksoy & Cinar, 2009; Akter et al., 2018) have been confirmed that the superficial epithelium is simple cylindrical glandular. It is formed by a single layer of epitheliocytes that lies on the basal membrane. These cells have a cylindrical shape, their height significantly exceeds the width (Fig. 1). Some of them reproduce by mitosis.

Epitheliocytes produce a mucous secret that covers the inner surface of the glandular part of the stomach. They are tightly arranged and connected by different types of contacts: simple, tight, interdigital, and desmosomes. In epithe-

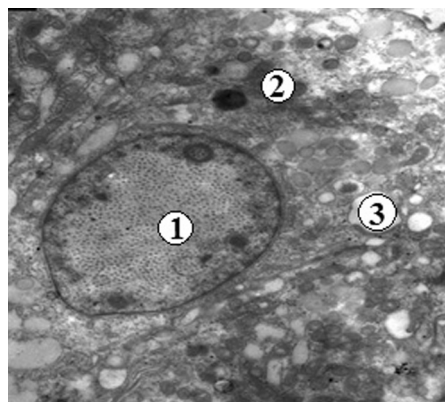


Fig. 1. The superficial epithelial cell of the mucosa of the glandular part of the stomach in a 180-day-old chicken. Electronogram: 1 – nucleus; 2 – cytoplasm; 3 – secretory granules. $\times 7000$

liocytes, two poles are clearly expressed – apical (directed to the external environment) and basal (located on a basal membrane). The microvilli are visible on their apical pole. However, in epitheliocytes, which are overflowing with the secrets, the microvilli are solitary and the apical surface of these cells is almost smooth. The nucleus is single, located in the area of the basal pole, and has a predominantly rounded shape. It has one nucleolus; heterochromatin is mainly locally fixed to the nucleolemma and scattered in places in the nucleoplasm. The cytoplasm of epitheliocytes has medium electron density. Near the nucleus, the tubules of the granular and agranular endoplasmic reticulum, ribosomes, and their clusters, the polyribosomes, are clearly expressed. Mitochondria are mainly concentrated in the middle part of the cytoplasm and near the apical pole. They are oval, rod-shaped, round, spindle-shaped with a matrix of medium electron density. Above the nucleus, there is a peculiar round or oval zone, the

contours of which are limited by mitochondria. There are noticeable elements of the Golgi complex, among which cisterns located among vacuoles and vesicles predominate. In the middle part of the cytoplasm of epitheliocytes, there are many secretory inclusions in the form of round, elongated-oval, spindle-shaped granules with different electron densities. They are located freely. Secretory granules are bounded by a membrane. Some of them, many of which are in the area of the apical pole, merge with each other or connect with the cell membrane. They released the secrets into the lumen of a stomach. In areas of the cytoplasm, which has no secretory inclusions, single tonofibrils are well visible, which intertwine with each other and rarely form bundles.

The lamina propria of the mucosa is formed by the loose fibrous connective tissue. It contains blood vessels and numerous superficial tubular glands, the ducts of which open on the surface of the mucosa (Fig. 2, 3). Mucus is found in the glands. Due to the numerous glands that

are located vertically to the surface of the mucosa, its relief has a peculiar appearance on histopreparations. It seems that the epithelium and lamina propria form papillae. The muscularis externa of the mucosa is an extension of the muscularis externa of the esophagus and is formed by smooth muscle tissue. It is not always well expressed, has an intermittent appearance. Its bundles of smooth muscle cells do not have a clear orientation.

The thickest layer of the mucosa is the submucosa, which is formed by the loose fibrous connective tissue with blood vessels and nerves. It contains complex (deep) glands, which are grouped into lobes. They correspond to the mammalian stomach glands (Matsumoto & Hashimoto, 2000). The particles of the deep glands are mostly polygonal, rarely rounded and are located in several layers (Fig. 4). Their typical feature is a complex system of excretory ducts. Each lobe has a collecting cavity into which the ducts of individual glands open. The collecting cavity is covered with a simple glandular epithelium, which in some

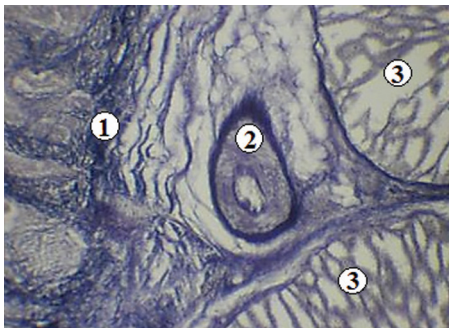


Fig. 2. The blood vessel in the lamina propria of the mucosa of the glandular part of the stomach in a 90-day-old chicken. Histopreparation: 1 – lamina propria; 2 – blood vessel; 3 – lobules of deep glands. Weigert staining, $\times 90$

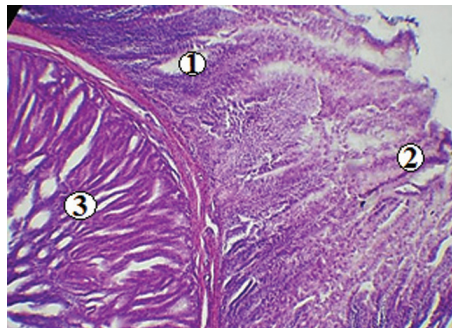


Fig. 3. Superficial tubular glands in the lamina propria of the mucosa of the glandular part of the stomach in a 90-day-old chicken. Histopreparation: 1 – lamina propria; 2 – superficial tubular glands; 3 – lobules of the deep gland. Staining with hematoxylin and eosin, $\times 63$

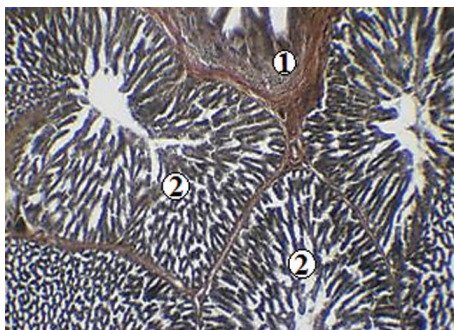


Fig. 4. The lobules of the deep glands of the glandular part of the stomach in a 30-day-old chicken. Histopreparation: 1 – lamina propria of the mucosa; 2 – lobules of deep glands. Van Gieson's staining, $\times 63$

lobes passes into the epithelial layer of the mucosa. The glands in the lobes are tightly adjacent to each other, and are located radially around the collecting cavity. From the latter originates the common excretory duct, which opens on the surface of mucosal elevation. These elevations are visible macroscopically

and are called glandular sacs, or papillae. In the intermediate zone of the glandular part of the stomach, the deep glands are absent, the submucosa thins. In the lamina propria of the mucosa of this zone, the glands inherent in the muscular part of the stomach appear, the secretion of which forms a thin cuticle, as a result of which the color of the mucosa becomes yellowish (Naletova, 2013).

Submicroscopic studies have shown that the lobules of the deep glands of the submucosa are formed by glandular cells (glandulocytes) with light and dark cytoplasm (Fig. 5, 6). Glandular cells have a single nucleus, in which chromatin clumps are well expressed. Synthesizing organelles, such as the granular endoplasmic reticulum, ribosomes, and the Golgi complex, are well developed among general-purpose organelles. Numerous mitochondria with a significant number of densely spaced cristae and numerous secretory granules are also visible in the cytoplasm. The secretory granules have a rounded shape, different sizes, and dif-

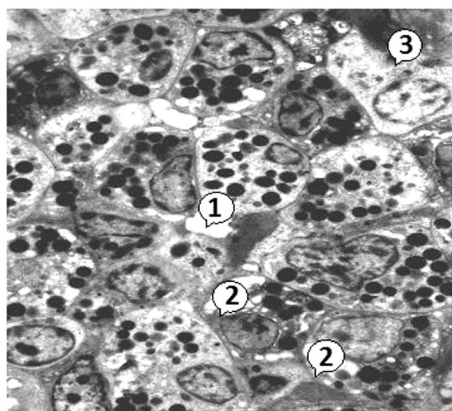


Fig. 5. The cellular composition of the submucosal lobule of the glandular part of the stomach in a 180-day-old chicken. Electronogram: 1 – lumen of the gland; 2 – glandular cells; 3 – plasma cell. $\times 3000$

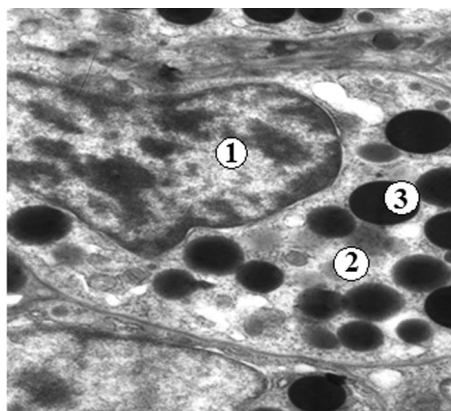


Fig. 6. The deep gland cell of the glandular part of the stomach in a 180-day-old chicken. Electronogram: 1 – nucleus; 2 – cytoplasm; 3 – secretory granules. $\times 8000$

ferent color intensities (black, gray, and gray with black areas).

According to some authors, glandulocytes combine the secretion of pepsinogen and hydrochloric acid (in birds, in contrast to mammals, these glands are not differentiated into major and parietal), which gave rise to calling them oxyntopeptic. Moreover, the synthesis of hydrochloric acid occurs in the apical pole of the glandular cell, and pepsinogen – in the basal (Mabelebele et al., 2014; Zhang et al., 2016). In the layers of the loose fibrous connective tissue that surrounds the lobules of the deep glands, there are well-defined blood vessels, including capillaries (Fig. 7).

The muscular membrane of the glandular part of the stomach is formed by smooth muscle tissue and is divided into three layers: inner and outer longitudinal and middle circular, of which the best developed is middle layer, and the least – the outer longitudinal layer (Fig. 8). According to some researchers, this

membrane in birds is two-layered: the inner longitudinal and outer – circular (Catroxo et al., 1997; Sayrafi & Aghagolzadeh, 2020), or vice versa inner circular and outer – longitudinal (Jeurissen et al., 1989; Kadhim et al., 2011). The serosa consists of loose fibrous connective tissue with blood vessels and nerve bundles, which is covered with mesothelium (simple squamous epithelium).

According to Naletova (2013), the muscularis externa of the mucosa of the intermediate zone connects with the muscular membrane and together they form an annular sphincter, which regulates the flow of feed into the muscular part of the stomach.

Morphogenesis of the glandular part of the stomach in chickens in the age aspect is manifested by changes in morphometric parameters of the thickness and the area of the membranes of its wall. Indicators of wall thickness between folds and in the area of mucosal folds increase from 1-day-old to 240-day-old (Table 1).

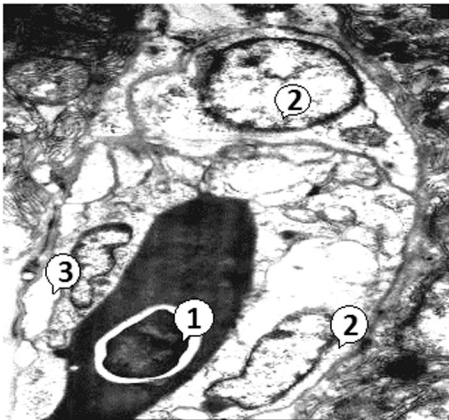


Fig. 7. Blood capillary in the submucosa of the glandular part of the stomach in a 180-day-old chicken. Electronogram:

1 – erythrocyte in the lumen of the capillary; 2 – endotheliocytes; 3 – pericyte. × 8000

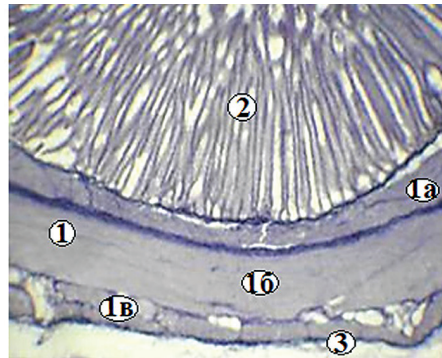


Fig. 8. The muscular membrane of the glandular part of the stomach in a 120-day-old chicken.

Histopreparation: 1 – muscular membrane: 1a – inner longitudinal layer, 1b – middle – circular layer, 1c – outer longitudinal layer; 2 – lobule of the deep gland; 3 – serosa. Weigert staining, ×90

1. The wall thickness in the glandular part of the stomach in chickens (M ± m, μm)

Age of chickens	Thickness	
	between the folds of the mucosa	in the area of the folds of the mucosa
1 day	1295.32 ± 37.27	1604.89 ± 46.29
30 days	2495.93 ± 197.45***	3323.84 ± 134.67***
60 days	3192.47 ± 148.37**	4124.25 ± 154.08**
90 days	3583.51 ± 92.44*	4536.67 ± 54.78*
120 days	3733.21 ± 101.58	4613.05 ± 102.72
150 days	3965.39 ± 162.07	5092.68 ± 108.42**
180 days	4127.30 ± 186.61	5156.84 ± 146.09
210 days	4218.95 ± 135.82	5553.99 ± 41.09
240 days	4223.23 ± 189.25	5561.32 ± 45.01
270 days	4219.56 ± 139.64	5531.99 ± 56.95
300 days	4212.23 ± 122.18	5509.10 ± 178.22
1 year	4204.90 ± 189.25	5502.66 ± 90.95
2 years	4201.24 ± 194.76	5506.33 ± 90.03
3 years	4208.57 ± 127.69	5524.62 ± 159.85

Note: * P < 0.05; ** P < 0.01; *** P < 0.001 compared with the indicator in previous group.

Thus, in one-day-old birds, this indicator between the folds of the mucosa is 1295.32 ± 37.27 μm and in the area of their folds – 1604.89 ± 46.29 μm, and in 240-day-old – 4223.23 ± 189.25 and 5561.32 ± 45.01 μm, respectively. That is, during this period, the wall thickness between the folds increases by 226.04% and in the area of folds – by 246.52%. The most intense wall thickness of the glandular part of the stomach increases in chickens from 1 to 30 days of age (92.69 and 107.11%, respectively). In chickens aged 270 days and older, this figure between the folds and in the area of the folds of the mucosa is almost unchanged

and ranges from 4201.24 ± 194.76 to 4219.56 ± 139.64 μm between the folds and from 5502.66 ± 90.95 to 5531.99 ± 56.95 μm in the area of folds.

The most developed membrane of the wall of the glandular part of the stomach, as noted above, is the mucosa (Table 2). Its area grows from the daily age (79.60 ± 0.90%) to the age of 180 days (82.14 ± 0.56%) by 3.19%. This indicator increases most intensively in chickens aged from one to 30 days (by 1.23%). In birds aged 210 days – 3 years, the area of the mucosa is almost unchanged and varies between 81.04 ± 0.47 and 82.01 ± 0.51%.

2. The area of the mucous, muscular, and serous membranes of the glandular part of the stomach in chickens (M ± m, %)

Age of chickens	Mucous membrane	Muscular membrane	Serous membrane
1 day	79.60 ± 0.90	17.07 ± 0.70	3.33 ± 0.22
30 days	80.58 ± 0.21	16.24 ± 0.36	3.18 ± 0.30
60 days	80.97 ± 0.84	16.20 ± 0.95	2.83 ± 0.45
90 days	81.38 ± 0.57	16.15 ± 0.59	2.47 ± 0.31
120 days	81.45 ± 0.43	16.09 ± 0.65	2.46 ± 0.32
150 days	81.48 ± 0.38	16.03 ± 0.43	2.49 ± 0.46
180 days	82.14 ± 0.56	15.54 ± 0.65	2.32 ± 0.33
210 days	82.01 ± 0.51	15.55 ± 0.46	2.44 ± 0.47
240 days	81.08 ± 0.36	16.46 ± 0.71	2.46 ± 0.38
270 days	81.27 ± 0.76	16.50 ± 0.76	2.23 ± 0.79
300 days	81.15 ± 0.31	16.35 ± 0.95	2.50 ± 0.66
1 year	81.27 ± 0.12	16.65 ± 0.58	2.08 ± 0.46
2 years	81.05 ± 0.38	16.71 ± 0.54	2.24 ± 0.70
3 years	81.04 ± 0.47	16.51 ± 0.59	2.45 ± 0.51

The area of muscular and serous membranes, on the contrary, decreases in birds aged from one (17.07 ± 0.70 and 3.33 ± 0.22%) to 180 days (15.54 ± 0.65 and 2.32 ± 0.33%) by 8.96 and 30.33%. A particularly sharp decrease in the area of the muscular membrane was registered in chickens from one to 30 days (by 4.86%), and serosa – from 30 to 60 days (by 11.01%). In birds aged 210 days – 3 years, the area of the muscular membrane varies between 15.55 ± 0.46 and 16.71 ± 0.54%. The area of the serosa in 210-day-old birds and older does not change and varies between 2.08 ± 0.46 and 2.50 ± 0.66%.

As noted above, lobules of deep glands are located in the submucosa of the glandular part of the stomach. Their number increases from one day of age

(22.40 ± 0.46) to 120 days (36.70 ± 0.76) by 63.84% (Table 3).

The most intense number of lobules of the deep glands increases in chickens from 30 to 60 days of age (by 20.96%). In 150-day-old chickens and older, the number of lobules practically does not change and varies between 34.80 ± 0.58 and 36.10 ± 0.71. The diameter of the lobules of the deep glands increases in chickens from the one-day (789.49 ± 31.30 μm) to 240-day (2990.41 ± 68.96 μm) age by 278.78%. This indicator increases most intensively in birds aged from 30 to 60 days – by 58.40%. In 270-day-old birds and older, the diameter of the lobules of the deep glands remains almost unchanged and ranges from 2921.01 ± 103.84 to 2945.89 ± 135.20 μm.

3. The number of lobules of the deep glands of the glandular part of the stomach and their diameter in chickens (M ± m)

Age of chickens	Number of lobes	Diameter, microns
1 day	22.40 ± 0.46	789.49 ± 31.30
30 days	27.20 ± 0.91***	1440.73 ± 94.69***
60 days	32.90 ± 0.55***	2282.08 ± 109.97***
90 days	33.70 ± 0.71	2541.32 ± 33.60*
120 days	36.70 ± 0.76*	2791.39 ± 103.35*
150 days	35.80 ± 0.68	2822.82 ± 177.68
180 days	35.50 ± 0.79	2876.50 ± 146.83
210 days	36.00 ± 0.75	2931.49 ± 75.91
240 days	36.10 ± 0.71	2990.41 ± 68.96
270 days	34.80 ± 0.58	2935.41 ± 104.68
300 days	35.20 ± 0.75	2921.01 ± 103.84
1 year	36.00 ± 0.75	2945.89 ± 135.20
2 years	35.10 ± 0.72	2936.72 ± 149.75
3 years	35.40 ± 0.93	2944.58 ± 168.32

Note: * P < 0.05; ** P < 0.01; *** P < 0.001 compared with the previous group.

Conclusions and future perspectives

The glandular part of the stomach in chickens has the form of a thick-walled tube, in which the mucosa is best developed. The superficial epithelium of this membrane is represented by cylindrical epithelial cells that lie on the basal membrane. They are interconnected by different types of contacts and have a well-defined polar differentiation. The lobules of the deep glands of the mucosa are formed by cells with well-developed synthesizing organelles and secretory granules.

Morphogenesis of the glandular part of the stomach in chickens in the age aspect is manifested by changes in morphometric parameters of the thick-

ness and the area of the membranes of its wall. The wall thickness increases in chickens up to 240 days of age, the area of the mucosa – up to 180 days, while the muscular and serous membranes decrease. In older birds, the thickness of the wall and the area of the esophageal membranes do not change significantly.

Further research should focus on the microstructure of the muscular part of the stomach in chickens in the age aspect.

References

- Abumandour, M. (2013). Morphological studies of the stomach of falcon. *Scientific Journal of Veterinary Advances*, 2(3), 30-40.
- Ahmed, Y., Kmel, G., & Ahmad, A. (2011). Histomorphological studies on the stomach of the Japanese quail. *Asian Journal*

- of Poultry Science, 5, 56-67. doi: 10.3923/ajpsaj.2011.56.67
- Aksoy, A., & Cinar, K. (2009). Distribution and ontogeny of gastrin and serotonin-immunoreactive cells in the proventriculus of developing chick, *Gallus gallus domesticus*. *Journal of Veterinary Science*, 10(1), 9-13. doi: 10.4142/jvs.2009.10.1.9
- Akter, K., Mussa, T., Sayeed, A., & Hai, M. A. (2018). Proventriculus of digestive tract of broiler. *Bangladesh Journal of Veterinary Medicine*, 16(1), 7-11. doi: 10.3329/bjvm.v16i1.37367
- Catroxo, M. H. B., Lima, M. A. I., & Cappellaro, C. E. (1997). Histological aspects of the stomach (proventriculus and gizzard) of the red-capped cardinal (*Paroaria gularis gularis*), Linnaeus, 1766). *Revista chilena de anatomia*, 15(1), 19-27. doi: 10.4067/S0716-98681997000100003
- Hassouna, E. M. A. (2001). Some anatomical and morphometrical studies on the intestinal tract of chicken, duck, goose, turkey, pigeon, dove, quail, sparrow, heron, jackdaw, hoopoe, kestrel and owl. *Assiut Veterinary Medical Journal*, 44, 47-78.
- Horalskyi, L. P., Khomych, V. T., & Kononskyi, O. I. (2005). *Osnovy histolohichnoyi tekhniki i morfofunktsional'ni metody doslidzhen' u normi ta pry patolohiyi* [Fundamentals of histological technique and morphofunctional methods of research in norm and in pathology]. Zhytomyr: Polissia.
- Jeurissen, S. H. M., Janse, E. M., Koch, G., & De Boer, G. F. (1989). Postnatal development of mucosa-associated lymphoid tissues in chickens. *Cell and Tissue Research*, 258, 119-124.
- Dahekar, N. M., Mamde, C. S., John, M. A., & Rohankar, R. U. (2014). Gross anatomical and histomorphological studies on proventriculus of Japanese quail. *Indian Journal of Veterinary Anatomy*, 26(1), 62-63.
- Dashiyeva, T. O. (1982). *Morfologiya organov pishchevareniya domashney utki v postnatal'nom ontogeneze* [The morphology of the digestive organs of domestic ducks in postnatal ontogenesis]. (Abstract of dissertation of Candidate of Veterinary Sciences). Ulan-Ude.
- Demirbag, E., Cinar, K., Tabur, M. A., & Asti, R. N. (2015). Histochemical structure of stomach (Proventriculus and Gizzard) in some bird species. *Journal of Natural and Applied Science*, 19(2), 115-122. doi: 10.19113/sdufbed.48385
- Kadhim, K. K., Zuki, A. B., Noordin, M. M., & Babjee, S. M. (2011). Histomorphology of the stomach, proventriculus and ventriculus of the red jungle fowl. *Anatomia, Histologia Embryologia*, 40(3), 226-233. doi: 10.1111/j.1439-0264.2010.01058.x
- Kharchenko, L. P. (2014). *Makroskopichna budova shlunka ptakhiv riznykh trofichnykh spetsializatsiy* [Macroscopic structure of the stomach of birds of different trophic specializations]. *Biolohiya ta valeolohiya*, 16, 62-70.
- Khomych, V. T., Usenko S. I., & Dyshliuk, N. V. (2020). Morphofunctional features of the esophageal tonsil in some wild and domestic bird species. *Regulatory Mechanisms in Biosystems*, 11(2), 207-213. doi: 10.15421/022030
- Langlois, I. (2019). The anatomy, physiology, and diseases of the avian proventriculus and ventriculus. *Veterinary Clinics: Exotic Animal Practice*, 6(1), 85-111. doi: 10.1016/S1094-9194(02)00027-0
- Mabelebele, M., Alabi, O. J., Ng'ambi, J. W., Norris, D., & Ginindza, M. M. (2014). Comparison of gastrointestinal tracts and pH values of digestive organs of Ross 308 broiler and indigenous. *Venda chickens fed the same diet. Asian Journal of Animal and Veterinary Advances*, 9, 71-76. doi: 10.3923/ajava.2014.71.76
- Matsumoto, R., & Hashimoto, Y. (2000). Distribution and developmental change of lymphoid tissues in the chicken proventriculus. *Journal of Veterinary Medical Science*, 62(2), 161-167. doi: 10.1292/jvms.62.161

- Naletova, L. A. (2013). Anatomical and histological characteristics of the glandular stomach of chickens and geese. Bulletin of the Buryat State University, 4, 186-188.
- Naletova, L. A. (2013). Anatomico-histological characteristics of the glandular stomach of chickens and geese [Anatomical and histological characteristics of the glandular stomach of chickens and geese]. Bulletin of the Buryat State University, 4, 186-188.
- Nasrin, M., Siddiqi, M. N. H., Masum, M. A., & Wares, M. A. (2012). Gross and histological studies of digestive tract of broilers during postnatal growth and development. Journal of the Bangladesh Agricultural University, 10(1), 69-77. doi: 10.3329/jbau.v10i1.12096
- Plokhinskiy, N. A. (1970). Biometriya [Biometrics]. Novosibirsk.
- Sayrafi, R., & Aghagolzadeh, M. (2020). Histological and histochemical study of the proventriculus (Ventriculus glandularis) of common starling (*Sturnus vulgaris*). Anatomia, Histologia, Embriologia, 49(1), 105-111. doi: 10.1111/ah.12495
- Seliverstova, L. S. (2018). Tendentsiyi rozvytku ta efektyvnosti funktsionuvannya rynku produktsiyi ptakhivnytstva v Ukraini [Development tendencies and peculiarities of functioning of the poultry market in Ukraine]. Efektyvna ekonomika, 1. Retrieved from <http://www.economy.nayka.com.ua/?op=1&z=6368>
- Vlasov, A. I., Yelsukov, K. A., & Kosolapov I. A. (2011). Elektronnaya mikroskopiya [Electron microscopy]. Moscow: MGU im. Bauman.
- Zhang, H., Peng, T. Ge. S., Zhong, S., & Zhou, Z. (2016). Microstructure features of proventriculus and ultrastructure of the gastric gland cells in chinese taihe black-bone silky fowl (*Gallus gallus domesticus* Brisson). Anatomia, Histologia, Embriologia, 45(1), 1-8. doi: 10.1111/ah.12164

Дишлюк Н. В. (2021). МОРФОГЕНЕЗ СТІНКИ ЗАЛОЗИСТОЇ ЧАСТИНИ ШЛУНКУ КУРЕЙ У ПОСТНАТАЛЬНОМУ ПЕРІОДІ ОНТОГЕНЕЗУ

Ukrainian Journal of Veterinary Sciences, 12(4): 66–78,
<https://doi.org/10.31548/ujvs2021.04.005>

Анотація. Знання морфологічних особливостей будови і функцій органів травлення створюють основу раціонального та ефективного використання кормів, профілактики та лікування шлунково-кишкових захворювань свійської птиці. У зв'язку з цим, великого значення набуває вивчення морфогенезу травної системи птахів та механізмів їхньої регуляції.

Об'єктом дослідження була залозиста частина шлунку (*proventriculus*) курей кросу Швер 579. Для макро- і мікроскопічних досліджень матеріал відібрали від птиці віком 1, 30, 60, 90, 120, 150, 180, 210, 240, 270 і 300 діб та 1, 2 і 3 роки, який фіксували в 10% розчині нейтрального формаліну й заливали в парафін відповідно до загальноприйнятої методики. Для субмікроскопічних досліджень матеріал відібрали від курей цього ж кросу віком 180 діб. На ультратонких зрізах вивчали будову епітеліоцитів поверхневого епітелію й секреторних клітин глибоких залоз. Цифрові показники результатів досліджень обробляли статистично за допомогою персонального комп'ютера з використанням програми Microsoft Excel.

Залозиста частина шлунку курей є безпосереднім продовженням стравоходу й має вигляд товстостінної трубки, яка утворена слизовою, м'язовою й серозною оболонками. Поверхневий епітелій слизової оболонки представлений епітеліоцитами циліндричної форми, які лежать на базальній мембрані. Вони з'єднані між собою різними типами

контактів і мають добре виражену полярну диференціацію. Часточки глибоких залоз утворені клітинами із добре розвиненими синтезуючими органелами та секреторними гранулами.

Морфогенез залозистої частини шлунку курей у віковому аспекті проявляється змінами морфометричних показників товщини і площі оболонок її стінки. Товщина стінки нерівномірно збільшується до 240-добового віку курей (між складками $4223,23 \pm 189,25$ і в ділянці складок $5561,32 \pm 45,01$ мкм). Найбільш розвинутою оболонкою стінки залозистої частини шлунку є слизова. Її площа збільшується (на $82,14 \pm 0,56\%$) до 180-добового віку курей, а м'язової й серозної оболонок зменшується (відповідно на $15,54 \pm 0,65$ і $2,32 \pm 0,33\%$). У птиці старшого віку показники товщини стінки і площі оболонок залозистої частини шлунку суттєво не змінюються.

Ключові слова: кури, шлунок, морфометричні показники, слизова оболонка, м'язова оболонка, серозна оболонка
