
THE STRUCTURE AND TOPOGRAPHY OF LYMPHOID TISSUE IN IMMUNE FORMATIONS OF INTESTINES IN DUCKS

T. A. MAZURKEVYCH, PhD, Associate professor of
Department of Animal Anatomy, Histology and Pathomorphology
named after Academician V. G. Kasianenko,
<https://orcid.org/0000-0002-1294-5939>

V. T. KHOMYCH, Doctor of Veterinary Sciences, Professor of
Department of Animal Anatomy, Histology and Pathomorphology
named after Academician V. G. Kasianenko,
<https://orcid.org/0000-0003-1366-0377>

National University of Life and Environmental Sciences of Ukraine
E-mail: mazur@faust.kiev.ua; gistology_chair@nubip.edu.ua

Abstract. *The aim of the study was to determine the structure and topography of lymphoid tissue in immune formations of the intestines (Peyer's patches, Meckel's diverticulum, apical diverticula) in the postnatal period of ducks' ontogenesis. Established that lymphoid tissue in these organs located in the tunica mucosa and tunica muscularis of the intestines' wall. From the one-day age of duck, the lymphoid tissue is found in the tunica mucosa of all studied structures and in the tunica muscularis of the apical diverticula, and in the tunica muscularis from 10–20-days of age in the location of Peyer's patches and the Meckel's diverticulum. Lymphoid tissue has three levels of structural organization. These are diffuse lymphoid tissue, primary lymphoid nodules and secondary lymphoid nodules. The presence of all levels of the structural organization of lymphoid tissue indicates its complete morphofunctional maturity. The complete morphofunctional maturity of the mucosal lymphoid tissue of Peyer's patches is reached on the 15 day of ducks' age, the mucosal lymphoid tissue of the Meckel diverticulum on the 20-day of age, and in the apical diverticula on the 10-day of age. The complete morphofunctional maturity of the muscular lymphoid tissue of Peyer's patches is reached on the 15–25 days of ducks' age, the muscular lymphoid tissue of the Meckel diverticulum on the 25-day of age, and in the apical diverticula on the 10-day of age. The present article provides the first time data summarizing the structure and topography of lymphoid tissue in the immune formations of the intestines, such as Peyer's patches, Meckel's diverticulum and apical diverticula of the Blahovarsky cross broiler ducks.*

Keywords: *ducks, intestine, Peyer's patches, Meckel's diverticulum, apical diverticula, lymphoid tissue.*

Introduction

The mucosa-associated lymphoid tissue (MALT) forms the basis of aggregated (Peyer's patches) and isolated lymphoid nodules of the intestine, appendix, Meckel's diverticulum, lymphoid throat ring of Pirogov-Valdeyer, laryngeal tonsils (Casteleyn et al., 2010). MALT is also can be found in the wall of the bronchi and tubular urinary-genital organs (Reese et al., 2006). The gut and bronchus-associated lymphoid tissues adjacent to the mucosal epithelium are often referred as GALT and BALT, respectively (Day and Schultz, 2011; Kaushansky et al., 2016). These tissues contain lymphocytes and antigen-presenting cells and are directly involved in initiation of adaptive immune responses (Neutral et al., 2001; Qi Bao-min et al., 2009, Day and Schultz, 2011). In birds, a majority of peripheral lymphoid organ tissue (approximately 70%) is localized in the mucosa of tubular digestive organs (Neutra et al., 2001), which may be explained for by the fact that most antigens enter through the digestive system (Forchielli and Walker, 2005). Previous studies (Kitamura, 1976; Georgescu et al., 2007) demonstrated that lymphoid tissues of the waterfowl (geese, musky ducks) digestive tract can be located not only in their mucosa, but also in the muscularis and serosa. Thus, the goal of this study was to localize and characterize lymphoid tissue in the waterfowl Peyer's patches, Meckel's diverticulum, and apical diverticula.

Materials and Methods

Intestines were obtained from the Blahovarsky cross broiler ducks of 1, 5, 10, 15, 20, 25, 30, 60, 90, 120, 150, 180, 210, 240 days old (6 ducks per group).

All the interventions and slaughter of the birds were performed in compliance with the requirements of the European Convention for the Protection of Vertebrate Animals Used for Experimental and Scientific Purposes, Strasbourg 1986 (European Convention for the Protection of Vertebrate Animals) and the Decree of the First National Congress on Bioethics (Reznikov, 2003).

Necropsy, sample collection, and histology were performed as previously described (Horalskyj et al., 2005). At first, the numbers and localization of the Peyer's patches (PPs) were determined. Dimensions of PPs, Meckel's diverticulum, and the apical diverticula were measured using calipers and centimeter ruler. Then, tissues were fixed in 10% neutral formalin for 24 hours and then sections of paraffin-embedded tissues (30–40 sections per sample; in 8 μ thickness) were stained with hematoxylin and eosin, by van Gieson, by Weigert, by Sthendman, and impregnated by Kelemen. The slides were examined via light field microscopy (MBS-2 (Russia), "Biolam" (Poland), and "Olympus" (Japan).

The arithmetic mean was determined statistically with error of the arithmetic mean (SD). Statistical analysis was performed by using StatSoft Statistica 13.1 (1998).

Results

PPs, Meckel's diverticulum, and apical diverticula were visually identified in the duck intestine. The lymphoid tissue of the duck duodenum and ileum were represented by one PPs, whereas the jejunum contained three PPs. Like pyloric tonsil in chickens (Casteleyn et al., 2010), duodenal PPs of duck locate at the beginning of the intestine. Accord-

ing to our research, it has the form of a cone, the base of which is directed to the ventriculus. In the jejunum of ducks, we found three PPs that form closed rings. They are in permanent locations and have a width of 5–10 mm (McGarry and Bourns, 1980), which is confirmed by our research. The ileum PPs of ducks is near the ileocecal compound and covers about half gut circumference (McGarry and Bourns, 1980). We obtained the same results in our previous studies. In ducklings of 15-day old and younger, the PPs localization and anatomic dimensions were only determined by using Helman's method (Romeys, 1954). In older ducks, however, PPs were easily detected without a need for any special methods. Overall, the duodenum, ileum, and jejunum PPs reached their maximum size by 150, 120, and 120–150 days of age, respectively.

The caecal tonsils that occur close to the ileo-caecal junction in chickens and turkeys do not exist in ducks (Shawky, 2000). Our observation confirmed the researches of other scientists that caecal tonsils are not present in ducks, but numerous PPs are noted (Fig. 1), some of which were localized at the basis of guts. The PPs chain of the left cecum was significantly longer than that of the right cecum. Similarly, the right cecum chain was noticeably wider. Overall, in the older birds, we observed longer PPs.

Georgescu et al. (2006) investigated Meckel's diverticulum in the most common types of domestic birds: domestic hen (*Gallus domesticus*) and three domestic web-footed fowl species: domestic duck (*Anas domesticus*), muscovy duck (*Cairina moschata*) and domestic goose (*Anser domesticus*). Dimensions of Meckel's diverticulum differ accord-

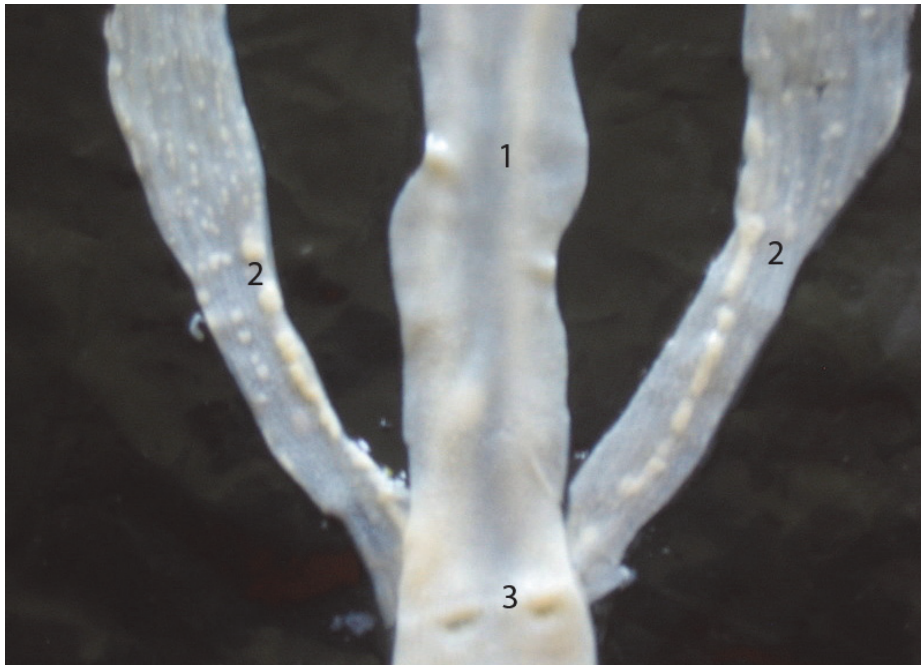


Fig. 1. Cecal Peyer's patches of 20-day-old duck (Helman's method):
1 – ileum; 2 – ceca with Peyer's patches; 3 – ileo-caecal junction

ing to species and age; the maximal development was observed at the age of 3–4 months at hens and at the age of 6–7 months at the web-footed fowl species. According to our studies, similar to PPs, Meckel's diverticulum reaches the maximal size on the 4–5 months (120–150 day) of ducks age.

The results also showed that the length and maximum thickness of the right and left apical diverticula were significantly different. Indices of the right apical diverticulum in most groups were greater than those of the left diverticulum.

There was no histological difference between the small and large intestine walls that either contained or lacked the PPs and apical diverticula. The wall canonically comprised tunica mucosa, tunica muscularis, and tunica serosa. The tunica mucosa had all four layers, epithelium, lamina propria, muscularis mucosae, and

tela submucosa, whereas the muscularis mucosae was poorly developed. Interestingly, as opposed to mammals, the duck duodenum tela submucosa lacked duodenal glands. The tunica muscularis consisted of well-developed inner circular and outer longitudinal smooth muscular tissue layers. The tunica serosa was formed by loose fibrous connective tissue and mesothelium. Finally, the muscularis mucosae was not detected at al.

The lymphoid tissue of pyloric tonsil and PPs in the hens are represented by diffuse lymphoid tissue, primary lymphoid nodules and secondary lymphoid nodules, which are located in their lamina propria of tunica mucosa and tela submucosa (Jerissen et al., 1989; Nagi and Olah, 2007). According to our research, the lymphoid tissue of the PPs of duodenum, jejunum, ileum, and caeca in ducks is represented by diffuse lym-

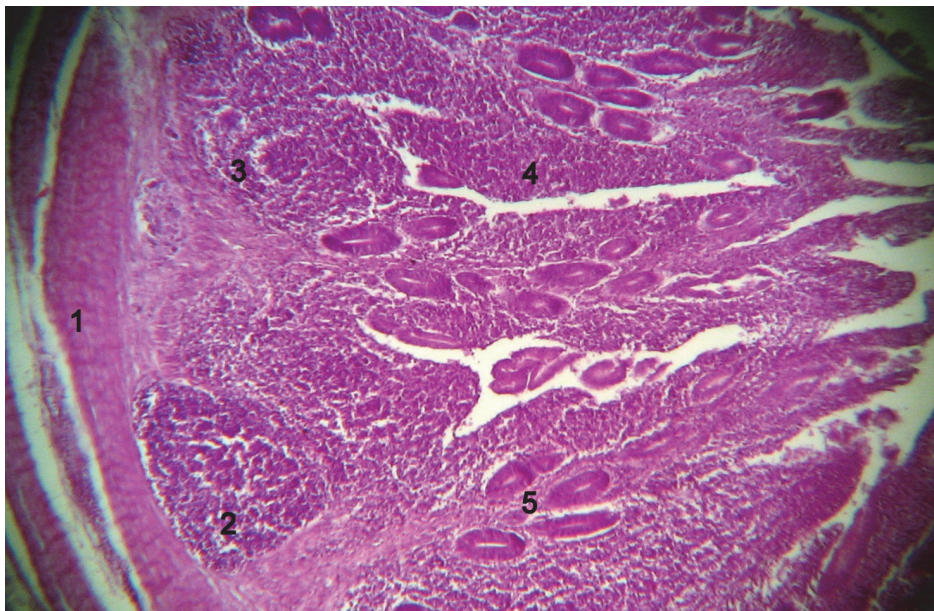


Fig. 2. Duodenum Payer's patch of 20-day-old duck: 1 – tunica muscularis; 2 – secondary lymphoid nodule in tela submucosa; 3 – primary lymphoid nodule in lamina propria mucosa 4 – diffuse lymphoid tissue; 5 – crypts.
Hematoxylin and Eosin staining, ×40

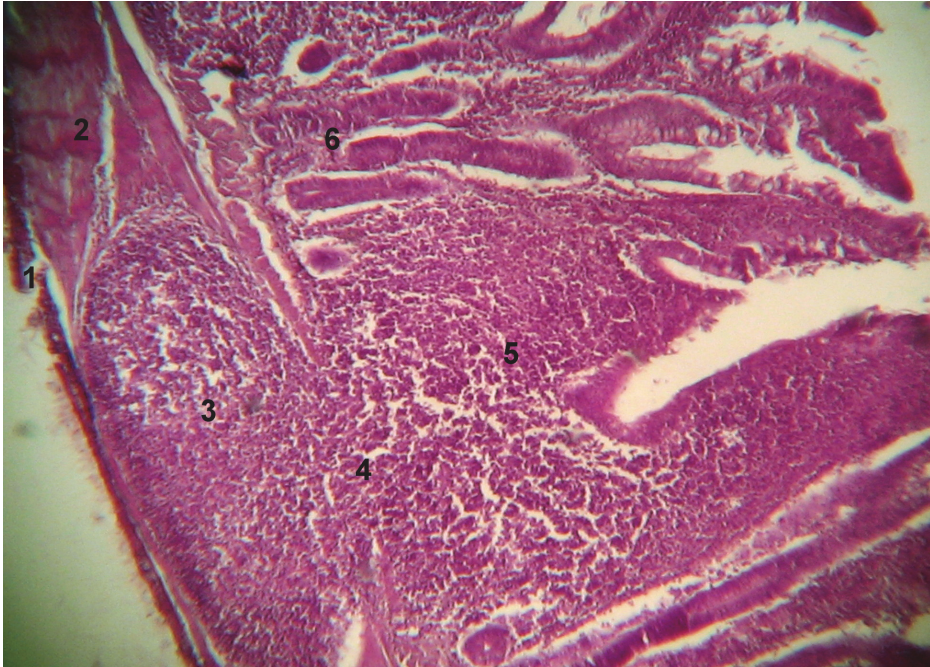


Fig. 3. Ileum Payers' patch of 20-day-old duck: 1 – tunica serosa; 2 – tunica muscularis; 3 – secondary lymph nodule in tunica muscularis; 4 – connection of lymphoid tissue of tunica muscularis and tunica mucosa; 5 – diffuse lymphoid tissue of tunica mucosa; 6 – crypts. Hematoxylin and Eosin staining, $\times 40$

phoid tissue, primary lymphoid nodules and secondary lymphoid nodules, which are located in their lamina propria of tunica mucosa and tela submucosa, as well as in the tunica muscularis.

The PPs lymphoid tissues were identified throughout the tunica mucosa and tunica muscularis of duodenum, ileum, and ceca in all the ducks that were at least 10 days old. In the birds of 20 days or older additional PP tissues were detected in the muscularis of the duck jejunum. In the tunica mucosa, PPs were observed in the lamina propria and tela submucosa (Fig. 2). Moreover, the epithelium of the tunica mucosa villi and crypts were infiltrated by numerous lymphoid cells. In the 210, 150, and 210-day-old ducks, the presence of lymphoid tissue has significantly increased in the tunica mucosa of

the duodenum ($64.63 \pm 1.28\%$), jejunum ($71.28 \pm 1.77\%$), and ileum ($82.69 \pm 1.14\%$), respectively. In contrast, the ceca PPs reached their maximum size ($46.43 \pm 1.78\%$) already in the 15-day-old birds. In the older birds, the tunica mucosa contained less lymphoid tissue. There were diffuse lymphoid tissue, primary lymphoid nodules, and secondary lymphoid nodules. Ratios of these lymphoid tissues varied between different age groups.

The lymphoid tissue was also detected in the tunica muscularis of the duodenum, ileum, and ceca in the ducks of 10 days or older, and in the jejunum of 20-day and older birds. Lymphoid tissue was placed in the internal (circular) layer of muscularis. In some places, it connected with lymphoid tissue of tunica mucosa (Fig. 3). The significantly greater presence of muscular lymphoid tissue in

the duodenum, jejunum and ileum was observed in the 150-day-old ducks ($41.31 \pm 1.13 - 45.28 \pm 2.48\%$). The older birds (240-day-old) had the least lymphoid tissue. The contents of muscular lymphoid tissue in the ceca increased constantly and in 240-day-old ducks covers $36.72 \pm 0.68\%$ of its area. The muscular lymphoid tissue was composed of diffuse lymphoid tissue, primary lymphoid nodules, and secondary lymphoid nodules. Only secondary lymphoid nodules, however, were detected in the tunica muscularis of the duodenum, jejunum, and ileum PPs in

the 15, 20 and 25-day and older ducks, respectively. Thus, secondary lymphoid nodules were the only level of structural organization of muscular lymphoid tissue in 60-240-day old ducks.

The content of diffuse lymphoid tissue in the tunica mucosa of Meckel's diverticulum increases to 30-60-day age of chickens (Glick, 1979). According Besoluk et al (Besoluk et al, 2002), lymphoid tissue of Meckel's diverticulum starts to develop from 5 to 7 weeks of age in gees. Jerissen et al. (Jerissen et al., 1989) noted that Meckel's diverticulum contained secondary lymphoid

1. The area of the lymphoid tissue and its forms in the mucosa and in the muscularis in the Meckel diverticulum, mean \pm SD, %, n = 6

Age, days	Mucosa in the Meckel diverticulum				Muscularis in the Meckel diverticulum			
	LT	DLT	PLN	SLN	LT	DLT	PLN	SLN
1	52,15 \pm 0,09	100	-	-	-	-	-	-
5	52,92 \pm 0,11	100	-	-	-	-	-	-
10	53,23 \pm 0,39	100	-	-	-	-	-	-
15	58,77 \pm 0,07	97,61 \pm 0,04	2,39 \pm 0,04	-	3,08 \pm 0,03	100	-	-
20	59,88 \pm 0,29	91,89 \pm 0,18	6,88 \pm 0,16***	1,23 \pm 0,06	9,92 \pm 0,05***	100	-	-
25	57,02 \pm 1,35	90,53 \pm 1,05	4,8 \pm 0,8**	4,67 \pm 0,62***	11,3 \pm 1,12	31,39 \pm 3,68***	8,89 \pm 2,49	59,72 \pm 4,93
30	57,59 \pm 0,22	89,89 \pm 0,6	1,47 \pm 0,19***	8,65 \pm 0,41***	12,21 \pm 0,2	21,54 \pm 1,31**	-	78,46 \pm 1,3**
60	57,58 \pm 2,58	89,01 \pm 0,89	1,14 \pm 0,41*	9,85 \pm 1,27	12,72 \pm 0,88	-	-	100*
90	57,46 \pm 0,19	81,5 \pm 0,17	1,02 \pm 0,07	17,48 \pm 0,12***	16,1 \pm 1,21*	-	-	100
120	55,95 \pm 1,51	74,02 \pm 6,46	0,98 \pm 0,27	25,0 \pm 6,2**	19,18 \pm 3,91*	-	-	100
150	56,3 \pm 0,35	79,83 \pm 0,55	-	20,17 \pm 0,55*	30,59 \pm 0,31**	-	-	100
180	56,13 \pm 0,25	82,87 \pm 1,97	-	17,13 \pm 1,86*	29,6 \pm 0,34	-	-	100
210	56,52 \pm 0,33	85,67 \pm 1,52	-	14,33 \pm 1,52*	26,77 \pm 1,72	-	-	100
240	56,01 \pm 2,6	95,95 \pm 0,8	-	4,05 \pm 0,8***	18,51 \pm 1,97**	-	-	100

Note: * - $p < 0,05$, ** - $p < 0,01$, *** - $p < 0,001$ compared to the previous age.

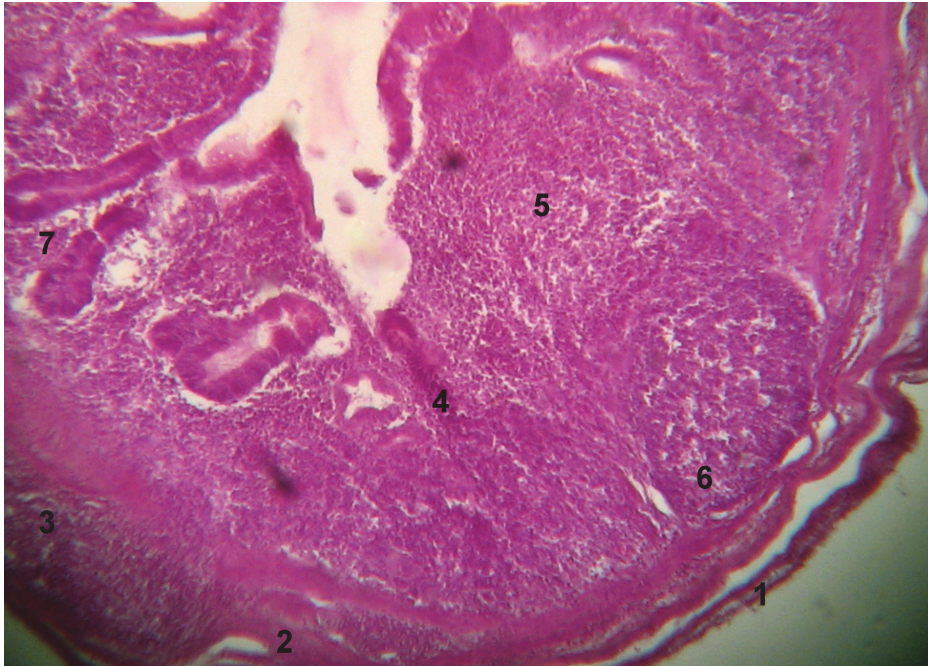


Fig. 4. Meckel's diverticulum of 25-day-old duck: 1 – tunica serosa; 2 – tunica muscularis; 3 – secondary lymphoid nodule in tunica muscularis; 4 – tunica mucosa; 5 – diffuse lymphoid tissue; 6 – secondary lymphoid nodule in tunica mucosa; 7 – crypt. Hematoxylin and Eosin staining, $\times 40$

nodules, starting from the 12-week of age in chickens. Our researches have established that in ducks, lymphoid tissue was consistently appear in the tunica mucosa in the animals of all ages (Table 1). In the 20-day old ducks the lymphoid tissue occupied approximately 60% of the tunica mucosa. Lymphoid tissue in the tunica mucosa of the Meckel's diverticulum in 20–120-day old ducks had diffuse lymphoid tissue, primary lymphoid nodules, and secondary lymphoid nodules (Fig. 4). However, in the older birds only diffuse lymphoid tissue and secondary lymphoid nodules were present in the tunica mucosa. Furthermore, lymphoid tissue in the tunica muscularis of Meckel's diverticulum detected in the 15-day or older ducks, contained diffuse lymphoid tissue, pri-

mary lymphoid nodules, and secondary lymphoid nodules. The secondary lymphoid nodules in tunica muscularis formed in ducks since 25-day age. The lymphoid tissue in the tunica muscularis of Meckel's diverticulum in ducks age from of 60 to 240 days is represented only by this level of structural organization. The area occupied by lymphoid tissue in tunica muscularis of Meckel's diverticulum increases up to 150-day-old ducks (Table 1).

Finally, the results showed that lymphoid tissue was localized in the tunica mucosa and tunica muscularis in the wall of apical diverticula in ducks of all studied age groups. Lymphoid tissue area increased up to 180-day-old of birds ($89.02 \pm 1.03\%$) in tunica mucosa of diverticula and up to 150-day-old of birds

(60.42±1.68%) in tunica muscularis. (Kitamura et al., 1976) reported that in apical diverticula of ducks, diffuse lymphoid tissue is located in the tunica mucosa, and secondary lymphoid nodules are in the tunica muscularis. Our observations reveal that diffuse lymphoid tissue and secondary lymphoid nodules in the apical diverticula of ducks are located both in the tunica mucosa and in the tunica muscularis. Mucosal lymphoid tissue composed of diffuse lymphoid tissue, primary and secondary lymphoid nodules. Muscular lymphoid tissue of diverticula represented by diffuse lymphoid tissue, and by secondary lymphoid nodules. The secondary lymphoid nodules were formed in diverticula wall (in both tunics) since from 10-day age of ducks.

As a result of all these histological analysis, it was found that the complete morphofunctional maturity of lymphoid tissue of tunica mucosa of PPs occurs at 15-day ducks age, the lymphoid tissue of tunica mucosa of Meckel's diverticulum – at 20-day, and in apical diverticula – at 10-day age. The complete morphofunctional maturity of lymphoid tissue of tunica muscularis of PPs occurs at 15–25-day age of ducks, the lymphoid tissue of tunica muscularis of Meckel's diverticulum – at 25-day, and in apical diverticula – at 10-day age.

References

1. Besoluk, K., Eken, E., Boydak, M., Tipirdamaz, S. (2002). Morphological studies on Meckel's diverticulum in geese (*Anser Anser Domesticus*). *Anatomia, Histologia, Embryologia* 31(5): 290–292.
2. Casteleyn, C., Doom, M., Lambrechts, E., Van den Broeck, W., Simoens, P., Cornillie, P. (2010). Locations of gut-associated lymphoid tissue in the 3-month-old chicken: a review. *Avian Pathology* 39 (3): 143–150.
3. Day, M. J., Schultz, R. D. (2011). *Veterinary Immunology: Principles and Practice*. Manson Publishing, London, 255.
4. levropeiska konventsiiia pro zakhyst khrebetnykh tvaryn, yaki vykorystovuiutsia dlia eksperymentalnykh i naukovykh tsilei [European convention for the protection of vertebrate animals used for experimental and other scientific purposes]. Strasburh, 18.III.1986. Available at; http://zakon4.rada.gov.ua/laws/show/994_137 (in Ukrainian).
5. Forchielli, M. L., Walker, W. A. (2005). The role of gut-associated lymphoid tissues and mucosal defence. *British Journal of Nutrition*. 93 (Suppl. I): 41–48.
6. Georgescu, B., Ciobotaru, E., Predoi, G., Cornila, N. (2007). Research concerning histostructure of cecal tonsils in some species of domestic birds. *Lucrari Stiintifice Medicina Veterinara* 40: 397–404.
7. Georgescu, B., Predoi, G., Cornila, N., Ciobotaru, E., Belu, C., Dumitrescu, I. (2006). Studies on Gross Morphology of Vitelline Diverticulum (Meckel's diverticulum) in Several Avian Domestic Species *Lucr. Șt. Med. Vet. Timișoara*, XXXIX: 388–393.
8. Glick, B. (1979). The avian immune system. *Avium disease*, 23(2): 282–290.
9. Horal's'kyy, L. P., Khomych, V. T., Konons'kyy, O. I. (2005). *Osnovy histolohichnoyi tekhniky i morfofunktsional'ni metody doslidzhen' u normi ta pry patolohiyi* [Fundamentals of histological techniques and morphological methods of investigation in normal and pathological conditions]. Polissya, Zhytomyr, 288 p. (in Ukrainian).
10. Jeurissen, S. H., Janse, E. M., Koch, G., De Boer, G. F. (1989). Postnatal development of the mucosa-associated lymphoid tissues in chickens. *Cell Tissue Res* 258(1): 119–124.
11. Kaushansky, K., Lichtman, M. A., Prchal, J. T., Levi, M. M., Press, O. W., Burns, L. J., Caligiuri, M. (2016). *Williams Hematology*,

- 9th edn. McGraw-Hill Education, New York: 2528.
12. Kitamura, H., Sugimura, M., Hashimoto, Y., Yamano, S., Kudo, N. (1976). Distribution of lymphatic tissues in duck caeca. *Jap J of Vet Res*, 24: 37–42.
 13. McGarry, R. C., Bourns, T. K. R. (1980). Annular bands of lymphoid tissue in the intestine of the mallard duck *Anas platyrhynchos*. *Journal of Morphology*, 163(1): 1–8.
 14. Nagi, N., Olah, I. (2007). Pyloric tonsil as a novel gut-associated lymphoepithelial organ of the chicken *J Anat*, 211: 407–411.
 15. Neutral, M. R., Mantis, N. J., Kraehenbuhl, J.-P. (2001). Collaboration of epithelial cells with organized mucosal lymphoid tissue. *Nature Immunology*, 2(11): 1004–1009.
 16. Qi Bao-min, Shang Ying-hui, Bao Han-xun (2009). The origin M cells of gut-associated lymphoid tissue in semi-muscovy duck. *Journal of Fujian Agriculture and Forestry University (Natural Science Edition)*, 3.
 17. Reese, S., Dalamani, G., Raspers, B. (2006). The avian lung-associated immune system: a review. *Vet.Res.*, 37: 311–324.
 18. Reznikov, O. H. (2003). Zahalni etychni pryntsyty eksperymentiv na tvarynakh. Pershyi natsionalnyi konhres z bioetyky [General ethical principles of experiments on animals. The first National Congress on Bioethics]. *Endokrynolohiia – Endocrinology*, Is. 8(1): 142–145 (In Ukrainian).
 19. Romeys, B. V. (1954). *Mikroskopicheskaya tehnik*a [Microscopic technology] 506. (In Russian).
 20. Shawky, S. (2000). Target cells for duck enteritis virus in lymphoid organs. *Avian Pathology*, 29(6): 609–616.
-

Мазуркевич Т. А., Хомич В. Т. (2019). Структура та топографія лімфоїдної тканини імунних утворень кишечника качок. *Ukrainian Journal of Veterinary Sciences*, 10(2): 4–12, <https://doi.org/10.31548/jvs2019.02.004>.

Анотація. Метою дослідження було визначити структуру та топографію лімфоїдної тканини в імунних утвореннях кишечника (плямки Пейєра, дивертикули Меккеля, сліпокишкові дивертикули) в постнатальному періоді онтогенезу качок. Встановлено, що лімфоїдна тканина в цих органах розташовується в слизовій і м'язовій оболонках стінки кишок. З добового віку качок лімфоїдна тканина зустрічається в слизовій оболонці всіх досліджених структур і в м'язовій оболонці сліпокишкових дивертикулів, а в м'язовій оболонці в місцях розташування плямок Пейєра і дивертикули Меккеля – з 10-20-добового віку. Лімфоїдна тканина має чотири рівні структурної організації. Це дифузна лімфоїдна тканина, передвузлики, первинні лімфоїдні вузли та вторинні лімфоїдні вузлики. Наявність всіх рівнів структурної організації лімфоїдної тканини свідчить про її повну морфофункціональну зрілість. Повної морфофункціональної зрілості лімфоїдна тканина слизової оболонки плямок Пейєра досягає в 15-добовому віці качок, лімфоїдна тканина слизової оболонки дивертикулу Меккеля – в 20-добовому та сліпокишкових дивертикулів – у 10-добовому віці. Повна морфофункціональна зрілість лімфоїдної тканини м'язової оболонки плямок Пейєра настає в 15–25-добовому віці качок, лімфоїдної тканини м'язової оболонки дивертикулу Меккеля – в 25-добовому, а також у сліпокишкових дивертикулах – у 10-добовому віці птиці. В статті наводяться узагальнюючі дані щодо структури та топографії лімфоїдної тканини імунних утворень кишечника, таких як плямки Пейєра, дивертикули Меккеля і сліпокишкові дивертикули у качок-бройлерів Благоварського кросу.

Ключові слова: качки, кишка, плямки Пейєра, дивертикули Меккеля, сліпокишкові дивертикули, лімфоїдна тканина