
CLINICAL PRESENTATION OF FIBRINOUS STREPTOCOCCAL UVEITIS IN CATTLE

V. O. DOROSHCHUK, *Candidate of Veterinary Sciences,*
Associate Professor of the Department of Surgery and Pathophysiology
Acad. I. O. Povazhenko,
<https://orcid.org/0000-0003-2826-5740>
National University of Life and Environmental Sciences of Ukraine
E-mail: dorviktor@gmail.com

Abstract. *Inflammation of the deep structures of the eye in cattle, in particular the vasculature, is rarely diagnosed, the cure rate is very small, due to insufficient study of diseases of the vascular tract of the eye.*

Inflammation of the vascular tract (uveitis) in cattle rarely becomes the object of scientific research, despite its prevalence.

Uveitis, like many other diseases of the organ of vision, often leads to blindness, such animals are forced to cull, causing significant economic damage to agriculture.

The disease has been poorly studied in productive animals, with the exception of horses, however, the literary sources concerning uveitis in cattle are isolated and unsystematic.

Bovine uveitis requires a thorough and comprehensive study of the features of etiopathogenesis, symptoms, diagnosis, and the development of rational therapy.

The article highlights the clinical symptoms of fibrinous uveitis of streptococcal etiology in cattle. Fibrinous uveitis is characterized by involvement in the inflammatory process of the iris and ciliary body.

The disease is accompanied by sequential complications: synechia; cataracts and glaucoma; lysis of the lens and vitreous body, which leads to subatrophy of the eye.

In the development of fibrinous uveitis streptococcal etiology should distinguish four stages: inflammatory hyperemia of the choroid; stage of fibrinous exudation and synechia; glaucoma and cataract stage, lens resection; enophthalmos.

The disease stages consist of two phases: the phase of septic inflammation; phase of autoimmunization (phakogenic uveitis).

Keywords: *uveitis, cattle, eye, fibrinous, streptococcal, organ of vision*

Introduction

Diseases of the deep structures of the eye in cows, in particular the choroid, are rarely diagnosed and even less likely to be treated due to insufficient knowledge of the diseases of the vascular tract of the eye.

Inflammation of the vascular tract (uveitis) in cattle, despite its frequent occurrence, very rarely becomes the subject of scientific research.

Uveitis, like many other diseases of the organ of vision, often leads to blindness, such animals are forced to be

rejected, which causes significant economic damage to agriculture.

Analysis of recent researches and publications

The disease has not been studied in productive animals: horses are a rare exception (Schwink, 1992, Witkowski et. al., 2016, McMullen et. al., 2017, Launois et. al., 2019). On the contrary, reports of uveitis in cattle are single and unsystematic (Laven, et. al., 2006, Hidayet Metin Erdogan, 2010, Schnee et. al, 2015).

This requires in-depth and comprehensive study of the features of etiopathogenesis, symptoms, diagnosis and development of rational therapy for cattle with uveitis, which makes the **purpose** of our work.

Materials and methods of research

The work was performed at Separated subdivision of NULES of Ukraine “Velykosnytynske Education and Research Farm named after O. Muzychenka”, Separated subdivision of NULES of Ukraine “Agronomic Research Station”, Separated subdivision of NULES of Ukraine “Education and Research Farm “Vorzel”. Dispensary examination was subjected to cattle of the black-horned breed aged from 3 months to 7 years, which was kept

in Separated subdivision of NULES of Ukraine. The control group included 143 healthy animals, experimental group included 137 uveitis patient. Clinical and statistical research methods used.

Results of the research and their discussion

The fibrinous streptococcal uveitis of the cattle is accompanied by changes at the level of the whole animal organism, as well as by typical changes on the part of the vision organ.

Sick animals are noticeably depressed, they buried their heads in the shade or looking for shaded places (due to photophobia). In most sick animals, wool is squished, loses its luster and looks dull. Indicators of body temperature, respiratory rate, pulse and scar reduction of animals in the control (clinically healthy) and experimental (patients with uveitis) groups are presented in table 1.

As we can see from the table, all the investigated clinical parameters of animals in the experimental group (patients with uveitis) are significantly different from those of the animals in the control group (clinically healthy animals). In uveitis patients, body temperature, respiratory rate, and heart rate were higher than the upper limit of normal. The incidence of rumen reduction in patients

1. Clinical indicators of the general animals condition of the control and experimental groups

Animals group	Body temperature (°C)	Breathing rate (per minute)	Heart rate (per minute)	Rumen reduction rate (per 2 minutes)
Control (clinically healthy), <i>n</i> = 143	38,2 ± 0,6	22,1 ± 1,3	58,8 ± 2,8	3,8±0,2
Experimental (uveitis patient), <i>n</i> = 137	39,7 ± 0,7	34,4 ± 1,1	84,6 ± 2,2	2,7 ± 0,22
<i>P</i>	< 0,05	< 0,05	< 0,05	< 0,05

2. Indices of average daily milk yield in cattle of control and experimental groups

Animals group	Daily milk yield, l
Control (clinically healthy), $n = 143$	$17,2 \pm 1,36$
Experimental (uveitis patient), $n = 137$	$11,6 \pm 1,24$
<i>P</i>	$< 0,05$

with uveitis in animals was almost at the border of the lower limit of normal, but atony of the ruminant alimentary canal in none of these animals was noted. Indicators of the general clinical condition indicate that the disease of cattle for uveitis is accompanied by fever, acceleration of respiratory rate and pulse, slowing of motility of the ruminant alimentary canal.

As we can see from the table, the average daily milk yield in patients with uveitis was 33 % lower than in the animals of the control group, indicate about the pronounced decrease in milk productivity.

Thus, given the indicators of the general clinical condition of the animal body and the level of milk production,

uveitis inflicts significant losses to cattle breeding, which in turn determines the importance of diagnosis and treatment of this disease.

The symptoms of uveitis are shown in table 3.

The table illustrates the clinical signs of uveitis were manifested by hyperemia in 137 animals, edema, partial depigmentation of the iris, smoothing its pattern and relief – 96. Often there was exudation into the eye chambers – 137. Exudate is often fibrinous, yellowish or greenish chamber of the eye, with a tendency to settle along the lower edge of the eye chamber. Pupils dilated, synechia may appear – 19, often posterior. Due to synechia, the pupils may become different in shape – 19. At the beginning of the disease, photophobia – 137,

3. Clinical manifestations of cattle uveitis, $n = 137$

Symptoms	Absolute amount, livestock	Relative amount, %
Hyperemia	137	100
Edema and iris depigmentation	96	70
Eye exudation	137	100
Camera exudation	137	100
Synechia	19	14
Irregular pupil shape	19	14
Total synechia	28	20
Injection of the perilimbal regions vessels	137	100
Photophobia	137	100
Corneal opacity and/or edema	89	65
Eyeball hypotension	97	71
Eye subatrophy	31	23
Eyeball rupture	28	20

superficial and deep injection of vessels of the preembolic area – 137, discharge of serous-catarrrhal exudate on the surface of the conjunctiva, with signs of inflammatory hyperemia of the binder 137. Relatively often, condensed exudate pellicles were recorded on the surface of the connective eye, which are relatively easy to remove with a tampon. In some cases, opacities were found, corneal edema was 89.

The disease was accompanied by partial loss of vision and often ended with subatrophy of the affected eye – 31. Signs of sympathetic ophthalmia (transition of inflammation to the contralateral healthy eye) in cattle with fibrinous uveitis streptococcal etiology did not occur.

One part of the animals had uveitis accompanied by signs of conjunctivitis (inflammatory hyperemia, exudation, photophobia, etc.); in other of the animal, conjunctivitis symptoms appeared at later stages of the disease, after symptoms of irritation and cyclitis.

Fibrinous exudation initiates a more severe course of uveitis, which is accompanied by various complications, primarily due to adhesion of the iris

mainly with the lens – posterior synechiae that bind the free edge of the iris with the lens capsule. The last can be full (circle) and incomplete (semicircle). This significantly complicates the act of accommodation (reduced vision), there is a strong pain due to the tension of the ciliary muscle, swelling of the iris increases, its bombardment occurs.

Full synechiae led to occlusion of the pupil and increased intraocular pressure, resulting in increased permeability of the hematopoietic barrier followed by opacification of the lens due to impaired nutrition of the latter, infiltration by exudate proteins and its cellular elements. Ophthalmologically, in the center and on the periphery of the lens, dark-gray arears were revealed.

The immunological response to the lens, which haven't immunological tolerance by lymphocytes, was accompanied by an autoimmune conflict. Sensitized lymphocytes that pass freely through the broken hematopoietic barrier cause gradual and steady lysis of the lens. This autoimmune conflict should be considered as phakogenic uveitis.

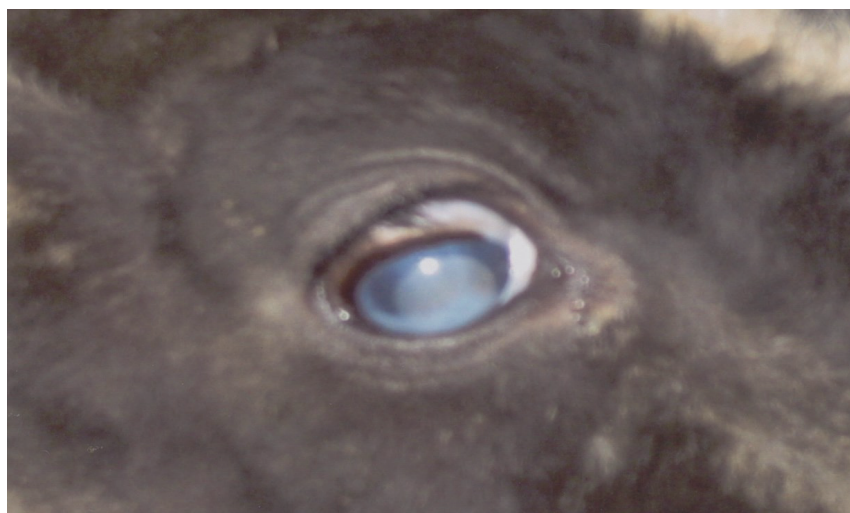


Figure 1. Camera exudation

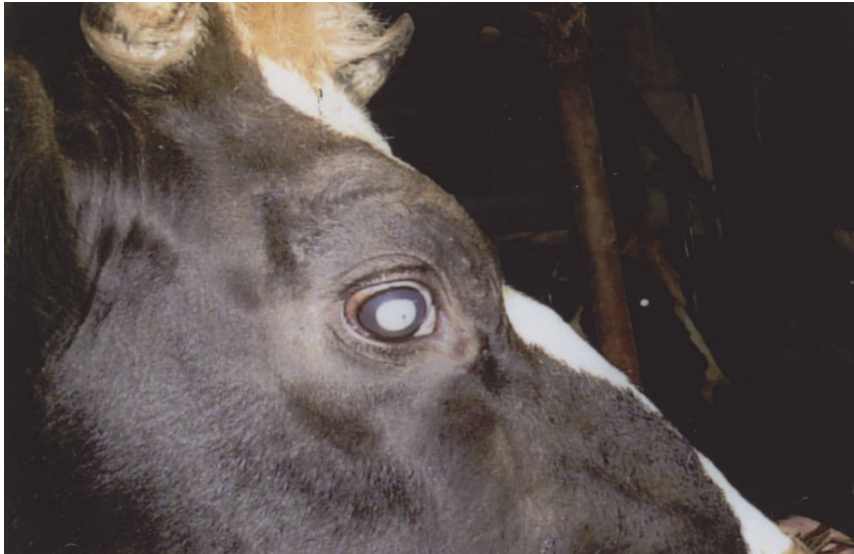

Figure 2. Posterior synechia and cataracts

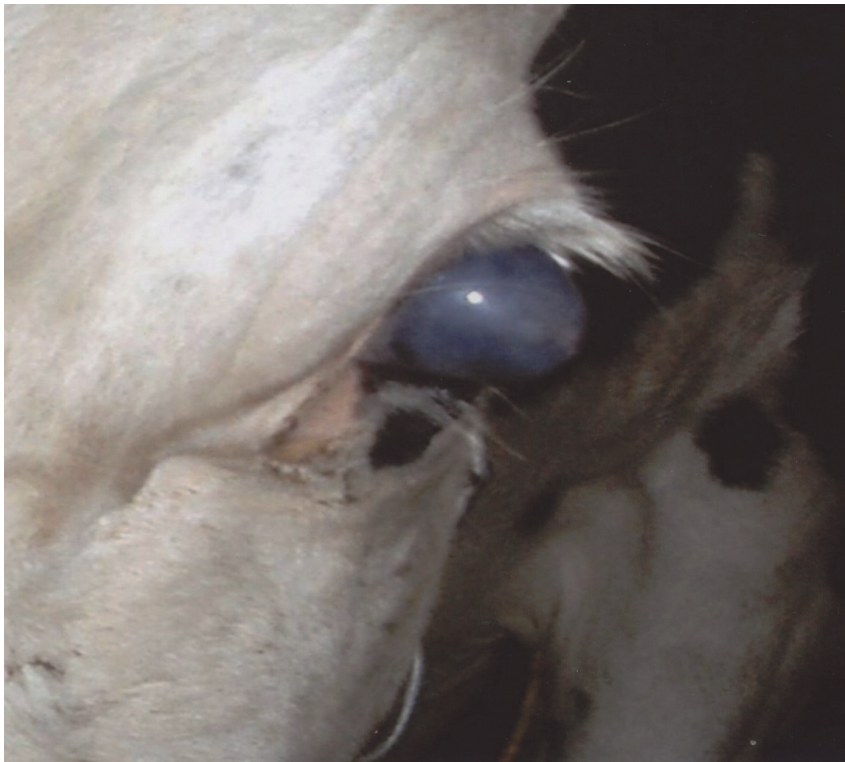

Figure 3. Eyeball baking in conjunction with glaucoma.

Another specific symptom of the disease is hypotension of the eyeball. It is detected by palpation of the turgor of the eye (digital tonometry), and then confirmed by tonometry according to Maklakov. The average pressure is 14–16 mm Hg. This symptom of the disease in our opinion is not critical to the condition of the eyeball, since hyposecretion of the liquid moisture of the ciliary body very quickly occurs hypersecretion, which, when incorrectly treated, leads to uveal glaucoma.

Another important pathogenetic link of fibrinous uveitis is glaucoma, which inevitably results from synechiae that disrupt the evacuation of ventricular fluid (Fig. 3).

Glaucoma is accompanied by retinal atrophy, and in severe cases (individual animals) can lead to rupture of the eyeball with the loss of the lens and the re-

jection of the last from the composition of the eyeball (fig. 4).

Autoimmune lysis of the lens is also accompanied by dystrophy and resorption of a large part of the vitreous body.

In the absence of a rupture of the eyeball (the vast majority of patients with uveitis), the rigidity of the eyeball is markedly reduced, its volume reduced, and it falls deeply into orbit. This phenomenon appears in ophthalmology called subatrophy of the eye.

Conclusions and future perspectives of the study

Fibrinous uveitis of streptococcal etiology in cattle is characterized by involvement in the inflammatory process mainly of the iris and ciliary body.

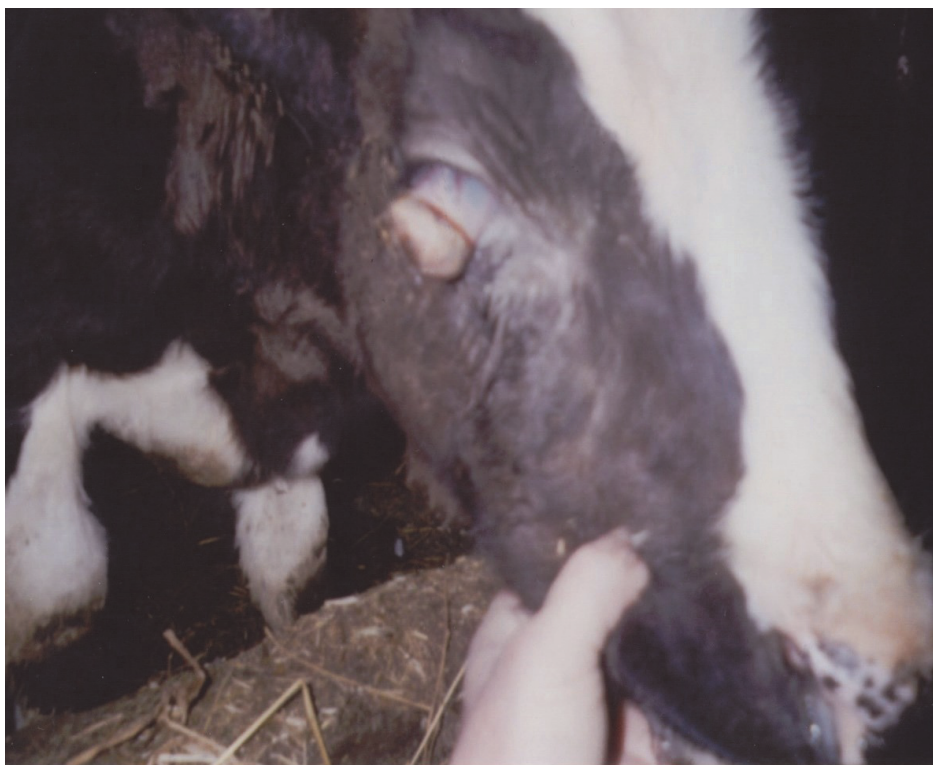

Figure 4. The rupture of the eyeball with the loss of the lens

The disease is accompanied by the sequential occurrence of the following complications: 1) synechia; 2) cataracts and glaucoma; 3) lysis of the lens and vitreous body, which leads to subatrophy of the eye.

In the course of fibrinous uveitis of streptococcal etiology of young cattle should be distinguished four stages: 1) inflammatory hyperemia of the vascular membrane; 2) stage of fibrinous exudation and synechia; 3) stage of glaucoma and cataracts, resection of the crystalline lens and 4 enophthalmos.

The stages of the disease are two phases: 1) the phase of septic inflammation; 2) the phase of autoimmunization (phakogenic uveitis).

References

- Schwink, Kay L. (1992). Equine Uveitis. *Veterinary Clinics of North America: Equine Practice*, 8(3): 557–574. doi:10.1016/S0749-0739(17)30441-8
- Witkowski, L., Cywinska, A., Paschalis-Trela, K., Crisman, M., Kita, G. (2016). Multiple etiologies of equine recurrent uveitis – A natural model for human autoimmune uveitis: A brief review. *Comparative Immunology, Microbiology and Infectious Diseases*, 44:14–20. doi: 10.1016/j.cimid.2015.11.004
- McMullen, R. J., Fischer, B. M. (2017). Medical and surgical management of equine uveitis. *Veterinary Clinics of North America: Equine Practice*, 33(3):465–481. doi:10.1016/j.cveq.2017.07.003
- Launois, T., González Hilarión, L., Barbe, F., Leurquin, C., Michel, J. (2019). Use of intravitreal injection of gentamicin in 71 horses with equine recurrent uveitis. *Journal of Equine Veterinary Science*, 77:93–97. doi:10.1016/j.jevs.2019.02.018
- Laven, R., Lawrence, K. (2006). An outbreak of iritis and uveitis in dairy cattle at pasture associated with the supplementary feeding of baleage. *New Zealand veterinary journal*, 54:151–2. Doi :10.1080/00480169.2006.36628.
- Hidayet Metin Erdogan (2010). Listerial Keratoconjunctivitis and Uveitis (Silage Eye) *Veterinary Clinics of North America: Food Animal Practice*, 26(3):505–510. Doi: 10.1016/j.cvfa.2010.09.003
- Schnee, C., Heller, M., Schubert, E., Sachse, K. (2015). Point prevalence of infection with *Mycoplasma bovoculi* and *Moraxella* spp. in cattle at different stages of infectious bovine keratoconjunctivitis. *The Veterinary Journal*, 203(1):92–96. Doi:10.1016/j.tvjl.2014.11.009

Дорощук В. О. (2020). КЛІНІЧНА КАРТИНА ФІБРИНОЗНОГО СТРЕПТОКОККОВОГО УВЕЇТУ У ВЕЛИКОЇ РОГАТОЇ ХУДОБИ. *Ukrainian Journal of Veterinary Sciences*, 11(1): 26–33, <https://doi.org/10.31548/ujvs2020.01.003>

Анотація. Запалення глибоких структур ока у великої рогатої худоби, зокрема судинної оболонки, діагностуються досить рідко, відсоток виліковуваності дуже малий через недостатню вивченість захворювань судинного тракту ока.

Запалення судинного тракту (увеїт) у великої рогатої худоби рідко стає об'єктом наукових досліджень, не дивлячись на його розповсюдженість.

Увеїт, як і багато інших захворювань органу зору, часто призводить до сліпоти. Таких тварин вимушено вибраковуюють, що наносить сільському господарству значних економічних збитків.

Захворювання мало вивчене у продуктивних тварин, винятком є коні, однак, літературні джерела, що стосуються увеїту у великої рогатої худоби є поодинокими і несистематизованими.

Увеїт великої рогатої худоби потребує глибокого і всебічного вивчення особливостей етіопатогенезу, симптомів, діагностики і розроблення раціональної терапії.

У статті висвітлені дані щодо клінічних симптомів фібринозного увеїту стрептококової етіології у великої рогатої худоби. Фібринозний увеїт характеризується залученням у запальний процес райдужної оболонки ока і циліарного тіла.

Захворювання супроводжується послідовним виникненням ускладнень: синехії; катаракти і глаукоми; лізису кришталику і склистого тіла, що призводить до субатрофії ока.

У розвитку фібринозного увеїту стрептококової етіології слід розрізняти чотири стадії: запальна гіперемія судинної оболонки ока; стадія фібринозної ексудації і синехії; стадія глаукоми і катаракти, резекція кришталика; енофтальм.

Стадії захворювання складаються із двох фаз: фаза септичного запалення; фаза аутоімунізації (факогенний увеїт).

Ключові слова: увеїт, велика рогата худоба, око, фібринозний, стрептококовий, орган зору

Подано до друку 24 січня 2020 року